

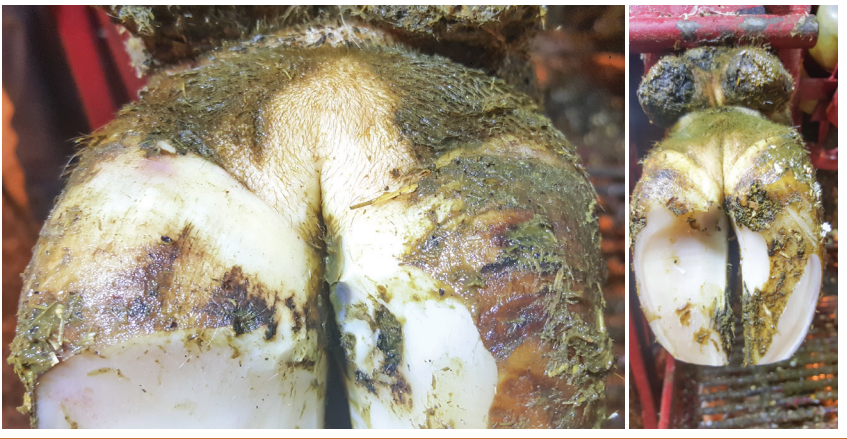

Break the DD Cycle

Jamie Sullivan of Ripple View Hoof Care recommends looking for these signs to identify digital dermatitis at its various stages.

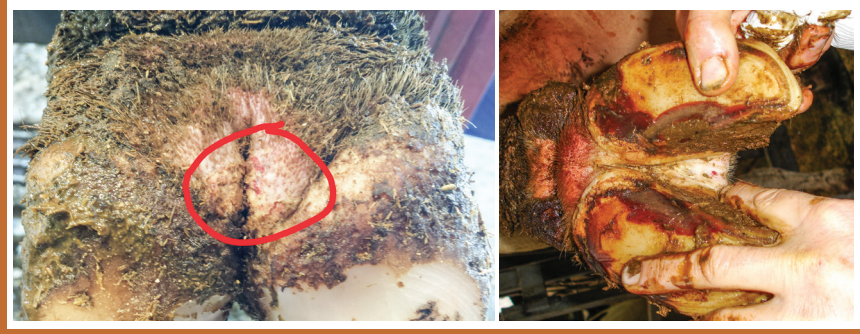M0

No DD lesion or chronic scar tissue. Normal skin and no pain to animal. THE GOAL!



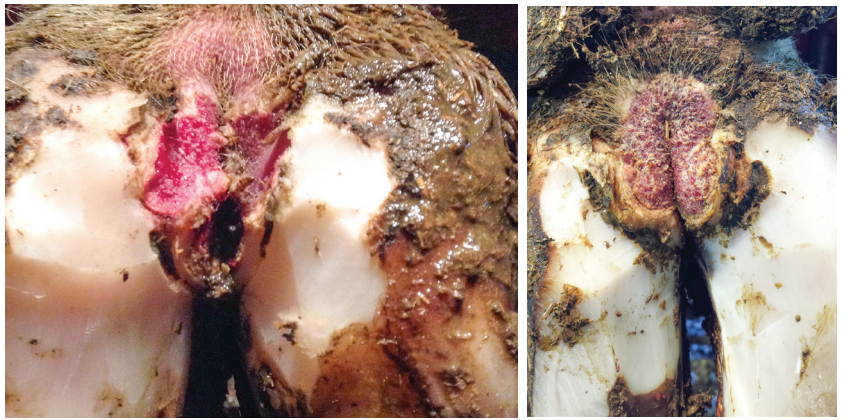
M1

Early lesion smaller than size of dime. Animal may or may not show signs of pain.



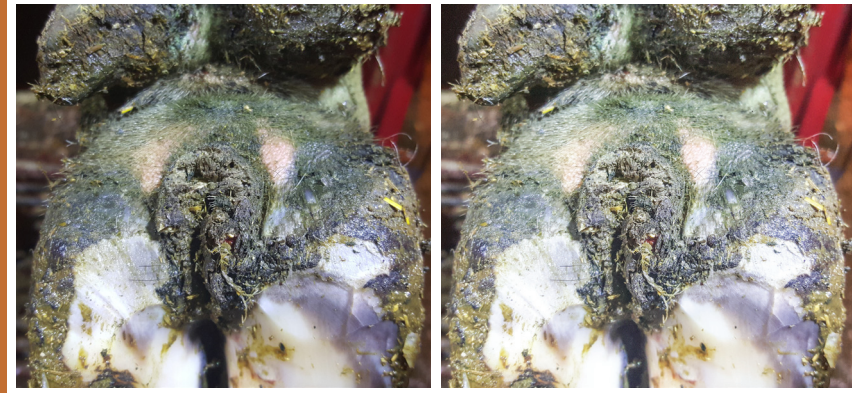
M2

Ulcerated lesion causing pain and discomfort. Treat ASAP!



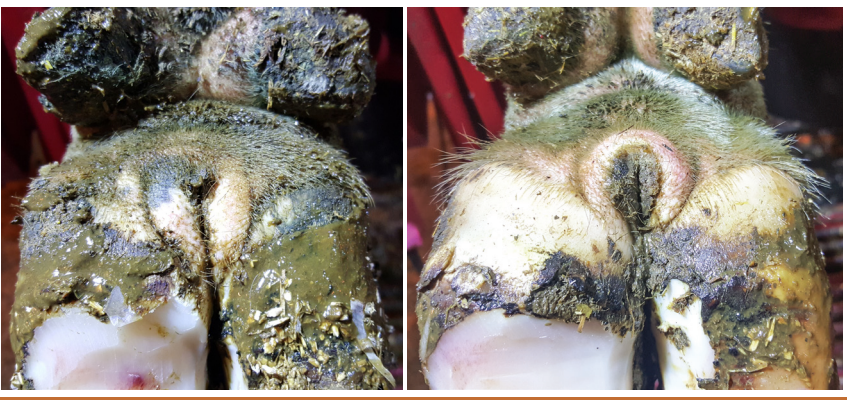M3

Healing lesion (scab) or dry blacken lesion with no pain/discomfort.



M4

Chronic cow thick skin (scar tissue). No pain/discomfort. Monitor for DD outbreaks.



M4.1

Chronic cow becoming affected with ulcerated lesion, indicating possible herd outbreak. Treat ASAP!

